

## A prospective case study: Comparing two surgical techniques: The closing and reverse wedge osteotomy for treating clinodactyly

Arwa Kasim Almajidy<sup>1</sup>, Sabah Hassan Naji<sup>2</sup>, Rand K. Almajidy<sup>3</sup>

<sup>1</sup> F.I.C.M.S, Plastic & Reconstructive Surgeon, Burn Specialty Teaching Hospital, Baghdad, Iraq.

<sup>2</sup> F.I.C.M.S Consultant Plastic Surgeon, Al-Wasity Plastic & Reconstructive Surgery Teaching Hospital, Baghdad, Iraq.

<sup>3</sup> M.Sc. Medical Engineering Neuroelectronic Systems, Department of Neurosurgery, Medical Center, University of Freiburg, Germany.

### ABSTRACT

**Background:** Clinodactyly or inclination of the digits, particularly the fifth digit, is a congenital anomaly of the hand that occurs in 1% to 19.5% of the population. This deformity requires reconstruction of both the functional and the aesthetic appearance of the finger, if it is severe, to avoid future growth deformity.

**Objective:** The study aims to review the outcomes and the complications associated with closing and reverse wedge osteotomy techniques for treating clinodactyly.

**Patients and Methods:** Ten patients' ten fingers with clinodactyly were submitted for reconstruction from March 2014 to May 2016 in the Al Wasity teaching hospital in Baghdad. They were treated using the closing and reverse wedge osteotomy techniques. In the closing wedge procedure, a wedge was removed from the most convex part of the middle phalanx. Subsequently, the finger is aligned in the midaxial plane and repaired with 2 K-wires. In the reverse wedge osteotomy, the wedge was rotated 180 degrees and reinserted into the bone gap with the wide end first. This buttressed the osteotomy open. Subsequently, the K-wires were inserted in retrograde fashion, maintaining the graft's position. Then, dressing was applied with the small splint from the PIP to the tip of the finger.

**Results:** After a 15-month follow-up, all the patients showed satisfactory results aesthetically and the functionally—with full range of motion. There was no recurrence in any case. Only one case had residual angulation and no major complications were encountered.

**Conclusion:** The closing and reverse wedge osteotomy was proven effective in treating clinodactyly. The closing wedge is simpler than the reverse wedge. The technical difficulty of reverse wedge osteotomy may make it a less appealing option to surgeons but the outcomes we had were rewarding, both techniques provided good overall correction of angulation in one stage, and straightforward procedure, with few complications, good aesthetic outcome and patient satisfaction with improved function.

**Keywords:** clinodactyly, closing wedge, reverse wedge

**Corresponding author:** Arwa Kasim Mohammed Almajidy, M B Ch B, F.I.C.M.S, Plastic & Reconstructive Surgeon, Burn Specialty Teaching Hospital, Baghdad, Iraq. Email: arwakasim11@yahoo.com

**Disclaimer:** The author has no conflict of interest.

**Copyright** © 2020 The Authors. Published by Iraqi Association for Medical Research and Studies. This is an open-access article distributed under the terms of the Creative Commons Attribution-Non Commercial License 4.0 (CCBY-NC), where it is permissible to download and share the work provided it is properly cited.

**DOI:** <https://doi.org/10.37319/iqnjm.2.1.4>

**Published online:** 15 January 2020

## INTRODUCTION

The term Clinodactyly (see Fig. 1) is derived from the two Greek words “klinen” and “daktylos,” meaning “to bend” and “finger,” respectively. The term describes a deviated finger in a radio-ulnar direction distal to the metacarpophalangeal joint <sup>(1)</sup>.

Splinting for clinodactyly is pointless. Correction of the skeletal anomaly requires either an osteotomy to realign the digit or resectioning of the longitudinal epiphyseal bracket to release the longitudinal growth potential of the shortened side of the digit <sup>(2)</sup>.

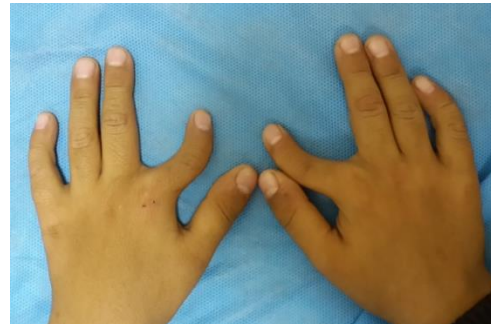Clinodactyly is frequently associated with little functional impairment. Mild deviation of the digit (<10° to 15°) may even be considered within the “normal” range. When the deformity is more severe, it can cause functional impairment or significant aesthetic deformity <sup>(3)</sup>.

### Classification of clinodactyly deformity

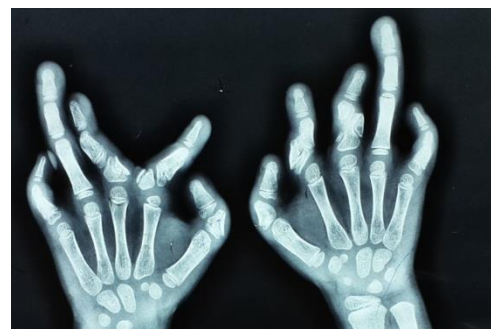Burke and Flatt <sup>(4)</sup> classified clinodactyly in 3 types:

- 1) Familial clinodactyly with a dominant inheritance. This type is usually not associated with other congenital anomalies;
- 2) clinodactyly in association with other syndromes;
- 3) clinodactyly secondary to epiphyseal injury such as a fracture or frostbite. This later condition is considered post-traumatic angular deformity rather than true congenital clinodactyly. Repetitive hand trauma among young athletes also reportedly results in this deformity <sup>(4)</sup>.

When the deformity is severe, the soft tissue deficiency in the concave part of the digit can limit the correction.



(a)



(b)

Figure 1: (a) A 6-year-old child with bilateral index and little finger clinodactyly. (b) A radiograph of 7-year-old child's hand with kissing delta phalanx clinodactyly, syndactyly and mental retardation <sup>(14)</sup>.

This can be overcome using closing wedge osteotomy to make the bony elements fit the soft tissue envelop or with opening wedge osteotomy. However, if the soft tissue is tight it needs to be lengthened. Z-plasty has been used to provide more soft tissue. A bipediced neurovascular step-advancement flap for soft tissue lengthening has also been used for opening the wedge repair of clinodactyly as D. M. Evans stated <sup>(5)</sup>.

All surgery for clinodactyly is difficult and the results are unpredictable. Therefore, it is best to avoid surgery in minor cases and to delay it until about 6 or 7 years of age if the deformity is pronounced <sup>(6)</sup>.

The degree of the deformity is inconsequential for meriting surgical correction. Some groups have suggested that it should be greater than 20 degrees (7).

## PATIENTS AND METHODS

This study involved 10 patients. The patients' data is presented in Table 1. The study was to evaluate the clinical and radiographic outcomes and complications of closing and reverse wedge osteotomy for treating the clinodactyly of the finger by measuring the pre-operative angulation for both the finger and its bony radiograph with a goniometer. This was followed by comparing it to the measurements of the same variables post-operatively to determine the clinical and radiographic

correction of the angulation after the surgery through the following equation:

Degree of correction = pre-operative angulation degree – post-operative residual angulation degree. Then, using T- test we determined the significance of the improvement in angulation after surgery.

We calculated the mean improvement based on the difference in the outcomes between the two different surgical techniques—namely the closing and reverse wedge osteotomy techniques.

Indications for surgical treatment included an angle greater than 35 degrees and specific functional limitations or dissatisfaction of the patient or parents with the appearance of the digit. The exclusion criteria were patients with associated deformities of the same digit

**Table 1:** Patient Data

Patient No.	Age (Years)	Gender	Finger Involved	Deviation	Associated Syndromes	Follow Up Duration (Months)
1	13	Female	Left thumb	Ulnar	None	24
2	7	Female	Right little	Radial	Syndactyly	19
3	8	Female	Left little	Radial	None	18
4	15	Female	Right thumb	Ulnar	None	13
5	13	Male	Left middle	Ulnar	None	8
6	9	Female	Right little	Radial	Mentally retarded Syndactyly	8
7	6	Male	Right middle	Ulnar	Rickets	7
8	16	Male	Left thumb	Ulnar	Syndactyly	6
9	13	Male	Right middle	Ulnar	None	6
10	6	Female	Left little	Radial	None	6

Patients with traumatic clinodactyly other than Burke and Flatt Type 3 clinodactyly were excluded. Patients treated with revision procedures were also excluded.

Congenital angular deformities due to bone abnormalities other than the middle phalanx were also excluded.

All our patients were subjected to routine physical examinations and pre-operative investigations. We measured the clinical angulation of the digit in the coronal plane with a standardized technique using a goniometer (Fig. 2)

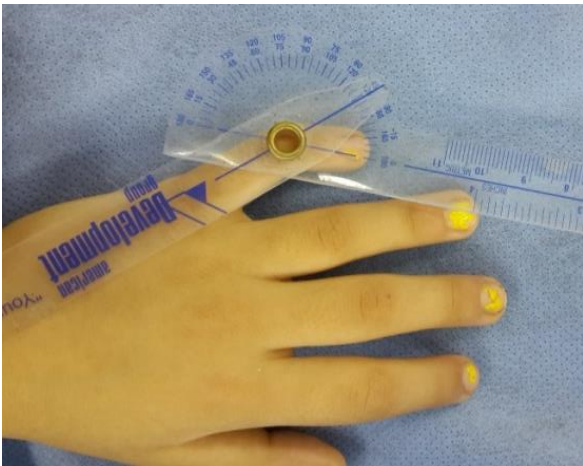

Figure 2: Clinodactyly angulation measurements.

### Surgical Technique

All the cases were done as day case surgeries under general anesthesia and arm pneumatic cuff tourniquet. All the surgeries were done under 3.5x magnification and in a supine position with the upper limb abducted and placed on a handstand for support. Subsequently, sterilization with povidone iodine and draping was done.

A dorsolateral longitudinal incision was made using a no. 15 blade at the middle phalangeal area over the most convex side of the finger, avoiding the joints. The incision was gradually deepened with blunt dissection until we reach

the extensor expansion on the dorsal aspect of the phalanx, then by blunt dissection, we freed the extensor mechanism so that it can be easily retracted to the other side of phalanx, and then the periosteum of the anomalous middle phalanx is incised (radially or ulnarly according to the side of the convexity) with no. 15 blade and reflected off the bone with periosteum elevator to expose the bone.

The wedge is marked on the bone with methylene blue. Subsequently, using fine a sharp osteotomy instead of a oscillating mini saw because the power saw blade removes larger amount of cortical bone (8). We proceeded with the osteotomy among pediatric and older patients and implemented both techniques—closing wedge osteotomy and reverse wedge osteotomy.

We made the distal followed by the proximal cut of the wedge. The size of the wedge varied according to the degree of angulation and the size of the bone (Fig. 3). However, we generally laterally removed about 2 to 5 mm bony wedge through the most convex part of the bone, and the osteotomy was completed with a bone cutter, leaving the periosteum intact.

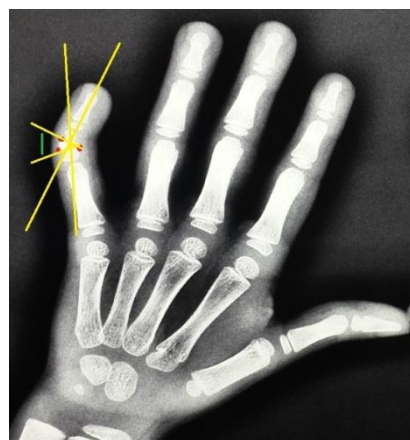


Figure 3. Wedge base length estimation technique (14).

In closing wedge osteotomy (Fig.4 and Fig.5), the digit was aligned after that step and the angular deformity was fully corrected in the midaxial plane.

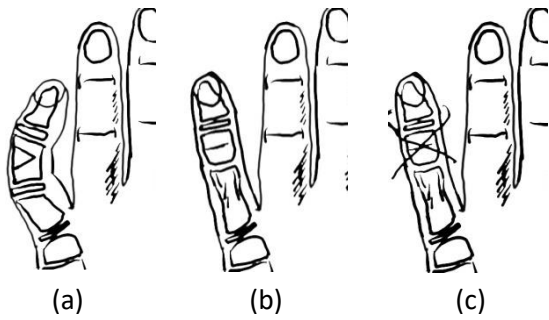


Figure 4: A closing wedge osteotomy technique through the abnormal middle phalanx stages: (a) wedge excision, (b) realignment of digit and (c) K-wire fixation<sup>(14)</sup>.

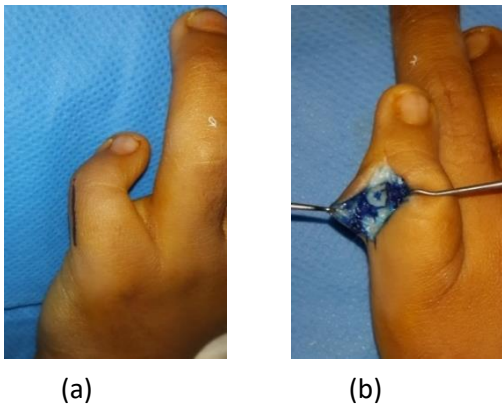


Figure 5: (a) Closing wedge osteotomy, skin marking , (b) Extensor mechanism and periosteum retracted, wedge marked<sup>(14)</sup>.

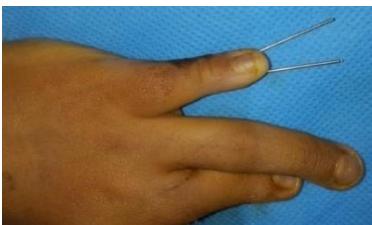

Figure 6: K-wires are fixed and skin is sutured

Two K-wires 1.4 mm [0.045 in.] or 0.9 mm [0.035 in.] (Depending on the size of digit) were passed in retrograde fashion from the pulp of the finger across the osteotomy transfixing the proximal interphalangeal (PIP) joint using a manual or power drill (Fig.6).

The same steps were followed in reverse wedge osteotomy (Fig. 7). The removed wedge was rotated 180 degrees and reinserted into the bone gap with the wide end (base of the wedge) first, thereby buttressing the osteotomy open (Fig. 8 and Fig. 9). Another incision was not required to achieve that. Then, the two K-wires were inserted, ensuring that the bone graft did not move during manipulation. Some patients had soft tissue tightness which required Z-plasties but tendon manipulation was not required.

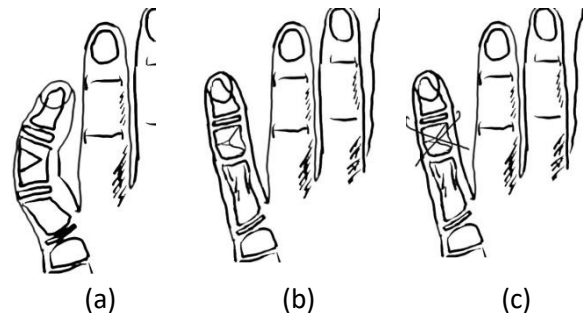


Figure 7: A reverse wedge osteotomy technique through the abnormal middle phalanx stages (a) wedge excision, (b) realignment of digit with the wedge inserted in the contralateral side and (c) K-wire fixation<sup>(14)</sup>.

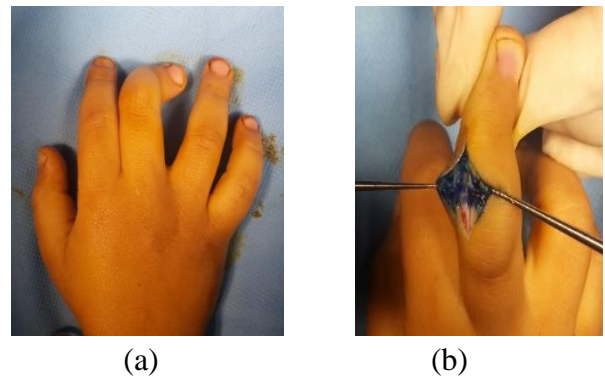


Figure 8: (a) A reverse wedge osteotomy marking and (b) exposure of bone.

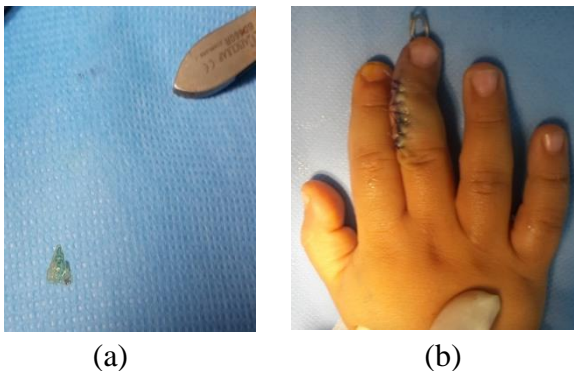


Figure 9: (a) Wedge bone graft and (b) K-wires fixed and skin sutured.

This is followed by the tourniquet being released in both techniques, after K-wire application and homeostasis “using bipolar cauterization.” The extensor mechanism is repositioned. The skin is sutured with horizontal mattress suture using a 4.0 Vicryl suture for children and 3.0 Prolene for older patients.

Antibiotic impregnated gauze was used to apply the dressing. It was directly applied over the wound. The second layer of fluffy gauze was applied and secured into position with crepe bandage. After applying the cotton, a small volar splint was used to cover the repaired finger from the tip to the PIP joint.

At the time of surgery, any residual angulation was measured and documented. The technique used (closing wedge or reverse wedge osteotomy) was chosen based on the length of the finger. Any patient who risked digit shortening due to the closing wedge osteotomy was operated on using reverse wedge osteotomy technique. The K-wires were kept for 6 weeks in all cases.

## RESULTS

Ten digits among ten patients fit the inclusion criteria. The mean duration of follow-up was 15 months (ranged 6-24 months). The clinical and radiographic angles between pre-operative and

post-operative measurements significantly improved. The degree of correction with a mean clinical improvement (correction of angulation) for all 10 cases was calculated to be 52.8 degree (Table. 2).

The mean clinical improvement for the closing wedge osteotomy technique cases was 48.83 while it was 58.75 for the reverse wedge osteotomy technique. A mean radiographic angle improvement of 51.8 degrees was calculated for all ten cases. The mean for the closing wedge osteotomy technique cases was 48 degrees while it was 57.5 degrees for the reverse wedge osteotomy technique.

The clinical angle between pre-operative clinical angle and final clinical angle ( $p < 0.05$ ,  $p = 0.000000022655$ ) significantly improved using the t-test. Additionally, the radiographic angle between pre-operative radiographic angle and final radiographic angle ( $p < 0.05$ ,  $p = 0.000000016731$ ) significantly improved.

There was no significant difference between immediate post-operative and final follow-up clinical angle ( $P = 1$ ) or radiographic angle ( $P = 1$ ), indicating the maintenance of corrected angulation post-surgery. (Fig.10 and Fig.11) shows the pre- and post-operative angulation).

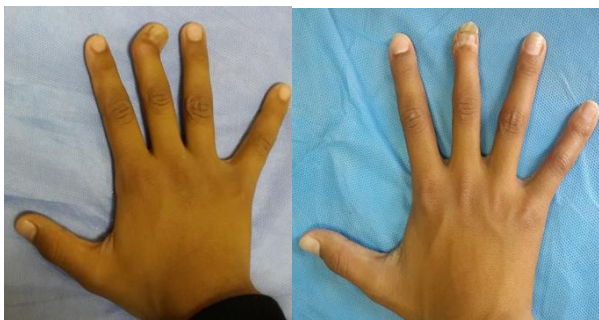Intra-operative or immediate major post-operative complications were not encountered. All the osteotomies healed without complications. One patient’s K-wire accidentally slipped in the 4<sup>th</sup> post-operative week (the other K-wire was fixed and the patient experienced normal healing and outcome). Based on the definition of residual angulation (any deformity greater than 10 degrees) or recurrence (deformity greater than

the initially corrected deformity), none of our patients developed recurrence. Only 1 patient had a residual deformity of 15 degrees after surgery. Pre-operatively, he had a non syndromic 85 degree radiographic angulation

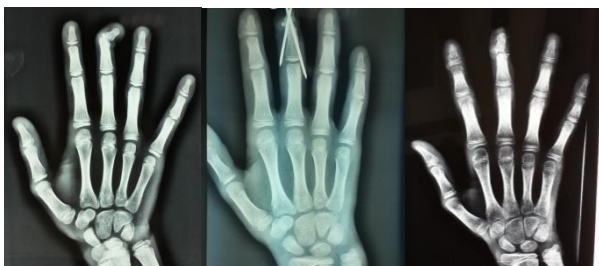at the middle finger which was severely affecting his hand function. After surgery his hand function and final clinical and radiographic angulation was 15 degrees with dramatic improvement of the finger function.

**Table 2:** The patients’ pre- and post-operative clinical and radiographic angles

Patient No.	Age (Years)	Type of Osteotomy	Clinical Angle (Degrees)			Radio Angle (Degrees)		
			Pre-operative	Post-operative	Final	Pre-operative	Post-operative	Final
1	13	Closing	50	8	8	48	8	8
2	7	Closing	45	0	0	45	0	0
3	8	Closing	55	0	0	50	0	0
4	15	Closing	65	5	5	65	5	5
5	13	Closing	45	0	0	45	0	0
6	9	Closing	48	0	0	50	0	0
7	6	Reverse	85	15	15	85	15	15
8	16	Reverse	65	0	0	65	5	5
9	13	Reverse	50	0	0	55	0	0
10	6	Reverse	50	0	0	50	0	0

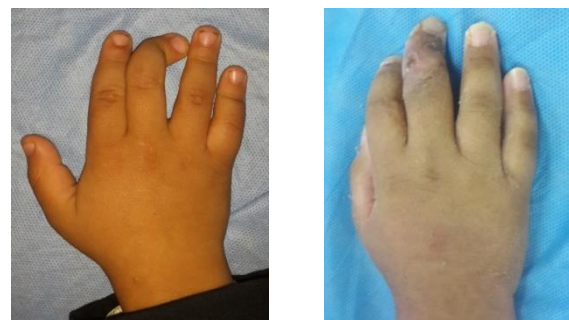

(a) (b)

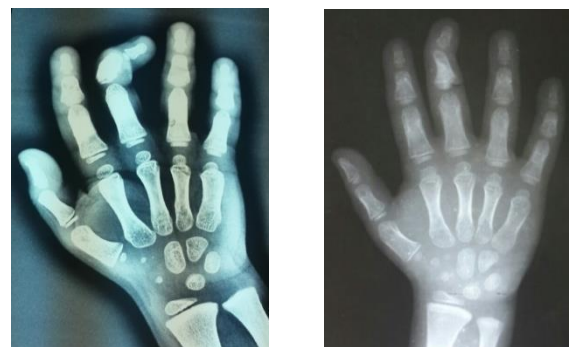

(c) (d) (e)

Figure 10: Closing wedge osteotomy case. (a) Rt. Middle finger clinodactyly (early childhood trauma) with epiphysial plate damage leads to asymmetrical growth. (b) Rt. Middle finger clinodactyly (post-operative result). (c) Pre-operative radiograph, (d) Early post-operative radiograph and (e) Late post-operative radiograph.



(a) (b)



(c) (d)

Figure 11: Reverse wedge osteotomy case. (a) Pre-operative and (b) post-operative photo of patient with Rt. Middle finger clinodactyly. (c) Preoperative and (d) post-operative radiography of patient with Rt. middle finger clinodactyly.

## DISCUSSION

We used both closing and reverse wedge osteotomy to treat clinodactyly angulation for evaluating the complications and results of the two techniques.

The clinical and radiographic angles for all cases between pre-operative and post-operative measurements significantly improved from 55.8 degrees to 3.5 degrees, with a mean clinical improvement of about 52.8 degrees for all ten cases. The mean clinical improvement for the closing wedge osteotomy technique cases was 48.83 while for the reverse wedge osteotomy technique cases was 58.75 and the mean radiographic angle improvement for all ten cases was 51.8 degrees. The mean for the closing wedge osteotomy technique cases was 48 degrees while it was 57.5 degrees for the reverse wedge osteotomy technique.

We used the reverse wedge osteotomy to treat severe angulation 85, 65, 50, 50 degrees respectively to preserve the finger length and prevent the shortening caused by the removal of a wedge during Closing osteotomy, also maintained the repair and avoided recurrence.

In our short follow up time (15 months), there was no recurrence of angulation among all cases and full range of motion for both PIP and DIP.

Our results about the closing wedge osteotomy technique are consistent with that of Ali Munawar et al who reviewed the outcomes of 25 digits among 17 patients with over 25 degrees angulation treated with closing wedge osteotomy. At a follow-up of 6 years, the mean clinical angulation had improved from 33 degrees to 9 degrees. The radiographic angulation had improved from 29 degrees to 5 degrees, the and range of motion was maintained <sup>(9)</sup>.

On the other hand, our results about reverse wedge osteotomy are consistent with the results of several studies. Carstam and Theander

treated 5 digits (1 thumb and 4 digits) with reverse wedge osteotomy; 4 had acceptable results. However, the wedge slipped out of position in one case, leading to loss of correction. The results achieved with this method were more rewarding in treating 4 digits at later ages <sup>(10)</sup>.

Burke and Flatt treated 2 digits (1 little and 1 ring) with reverse wedge osteotomy for proximal phalanx involvement and had an average correction of 33 degrees with a maintained total arc of motion <sup>(4)</sup>.

Al-Qattan has published his surgical results about 10 index fingers using a closing wedge osteotomy and recommended that physio lysis should be used early and that close or open wedge osteotomy should be implemented if deformity persists <sup>(11)</sup>.

Piper Samantha L et al. retrospectively reviewed the opening wedge osteotomy technique for isolated congenital clinodactyly of a little finger of 13 digits in 9 patients. All had greater than 20 degrees of pre-operative clinical angulation. Mean age at the time of surgery was 11 years. All the digits displayed significant improvement (mean, 32 degrees) in clinical and radiographic angles after surgery. This improvement was maintained at the final follow-up in 12 digits <sup>(7)</sup>.

A distal radius bone graft was used among older children with deformities greater than 45 degrees, but they have started using distal radius auto graft in all cases with a visible gap after opening the osteotomy to prevent non-union and recurrent angulation after this case experienced recurrence. The three digits developed stiffness at the distal interphalangeal joint post-operatively and one digit had a recurrent deformity at the final follow-up. We did not have joint stiffness or recurrence in our cases. Additionally, there was no need to do bone grafting other than the extracted wedge. Light and Ogden warned against placing a bone graft into an opening wedge osteotomy for fear of creating an epiphysiodesis that could tether



phalangeal growth (12). Longer-term follow-up will be required to evaluate this further. Alanna A. Gordon showed that the post-operative change in angulation was found to be significantly different depending on the surgical technique used (13). The digits corrected with reverse wedge osteotomies showed little to no change in angulation during the post-operative period. However, digits corrected with closing wedge osteotomies displayed a significant increase in angulation between the immediate post-operative and final follow-up measurements and showed that post-operative changes in angulation or recurrence were not significantly associated with gender, patient age at the time of surgery, the type of digit corrected, coexisting congenital syndromes, or the presence of additional hand abnormalities.

## CONCLUSIONS

Closing and reverse wedge osteotomy have proven to be effective in treating clinodactyly. The closing wedge is simpler than reverse wedge which requires precise surgical and technical judgment about the width of the wedge and manipulation of the graft. Both techniques provide good overall correction of angulation in one stage and are straightforward procedures. With a few complications, they can have good aesthetic outcomes and patient satisfaction with their improved functions. The technical difficulty of reverse wedge osteotomy may make it a less appealing option to surgeons but our outcomes about maintaining the length of the digit and treating severe angulations were rewarding. More follow up time is essential to understand the difference between effects of the two techniques on the length of the finger in the pediatric group and the recurrence of angulation with growth.

## REFERENCES:

1. Mathes SJ, Hentz VR. Part 2. The hand and upper limb. In: Plastic Surgery. 2nd ed. Saunders Elsevier; 2006. p. 295-7.
2. Wolfe S, Pederson W, Kozin SH. Part VI. The pediatric hand: Deformities of the hand and fingers. In: Green's Operative Hand Surgery. 6th ed. Elsevier Health Sciences; 2012. p. 1353.
3. Thorne CH. Part VIII. Hand: Common congenital hand anomalies. In: Grabb and Smith's Plastic Surgery. 7th ed. 2014. p. 895.
4. Burke F, Flatt A. Clinodactyly. A review of a series of cases. Hand [Internet]. 1979 Oct;11(3):269-80. Available from: <http://www.ncbi.nlm.nih.gov/pubmed/520870>
5. Evans DM, James NK. A bipediced neurovascular step-advancement flap for soft tissue lengthening. Br J Plast Surg. 1992;45(5): 380-4.
6. Georgiade GS. Congenital hand deformity. In: FACS Plastic, Maxillofacial and Reconstructive Surgery, Section 8. 3rd ed. 1997. p. 98.
7. Piper SL, Goldfarb CA, Wall LB. Outcomes of opening wedge osteotomy to correct angular deformity in little finger clinodactyly. J Hand Surg Am [Internet]. 2015 May;40(5): 908-913. Available from: <https://linkinghub.elsevier.com/retrieve/pii/S0031938416312148>
8. Dobyns, Wood, Bayne. Congenital hand deformities. In: Operative Hand Surgery. New York Churchill Livingstone; 1993. p. 426.
9. Ali M, Jackson T, Rayan GM. Closing wedge osteotomy of abnormal middle phalanx for clinodactyly. J Hand Surg Am [Internet]. 2009;34(5): 914-8. Available from: <http://dx.doi.org/10.1016/j.jhsa.2009.01.007>
10. Carstam N, Theander G. Surgical treatment of clinodactyly caused by longitudinally bracketed diaphysis ("delta phalanx"). Scand J Plast Reconstr Surg. 1975;9(3): 199-202.
11. Al-Qattan MM. Congenital sporadic clinodactyly of the index finger. Ann Plast Surg [Internet]. 2007 Dec;59(6): 682-7. Available from: <http://www.ncbi.nlm.nih.gov/pubmed/18046153>
12. Light TR, Ogden JA. The longitudinal epiphyseal bracket: Implications for surgical correction. J Pediatr Orthop [Internet]. 1981;1(3): 299-305. Available from: <http://europepmc.org/abstract/MED/6801087>
13. Gordon AA. Changes in angulation and phalangeal length of fingers and thumbs following surgical

treatment for congenital clinodactyly [Internet]. Boston University-School of Medicine; 2014. Available from: <https://hdl.handle.net/2144/14696>

14. Almajidy AKM. Closing and reverse wedge osteotomy techniques for the treatment of clinodactyly. The Iraqi Board of Medical Specializations in Plastic and Reconstructive Surgery; 2015.